

Patient Name : **Doe, John**

Patient Rec. #:

Date of Birth: 06/21/1946      Age: 69

Sex: Male

Date Collected: 01/12/16

Date Received: 01/12/16

Date Reported: 01/18/16

Specimen Number: **S16-009696**

UP ID:

Ordering Client: THE BEST DOCTOR, MD

Ordering Physician: THE BEST DOCTOR MD

Client Address: 1 WESTCHESTER PLAZA

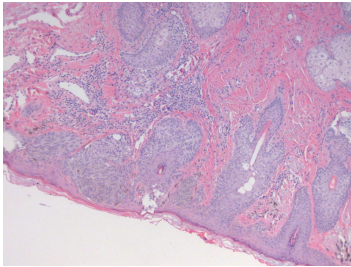
ELMSFORD, NY 10523

Telephone: (914) 307-1678

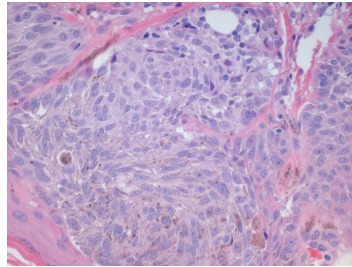
Fax: (914) 345-3064

CC Physician:

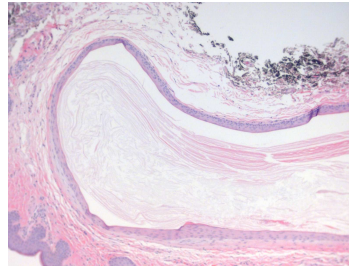
## PATHOLOGY REPORT



A Junctional atypia



A Atypical melanocytic proliferatn



B Benign epithelial cyst

### Specimen A- Nasal lesion

#### DIAGNOSIS:

**MALIGNANT MELANOMA IN SITU**

#### GROSS DESCRIPTION:

Received in formalin, a 0.8 x 0.5 x 0.2 cm tan ellipse of skin. On surface is a brown lesion measuring 0.2 x 0.2 cm. Specimen is inked black for margins, trisected, and entirely submitted in one cassette.

### Specimen B- Left eyelid/brow lesion

#### DIAGNOSIS:

**BENIGN EPITHELIAL CYST**

#### GROSS DESCRIPTION:

Received in formalin, a 1.0 x 0.4 x 0.2 cm tan/white skin. Specimen is covered in blue ink. Specimen is inked black for margins, trisected, and entirely submitted in one cassette. //sp

### CLINICAL HISTORY

Facial lesions

Electronically Signed by: Alliance Pathologist M.D.

Date: 01/18/2016