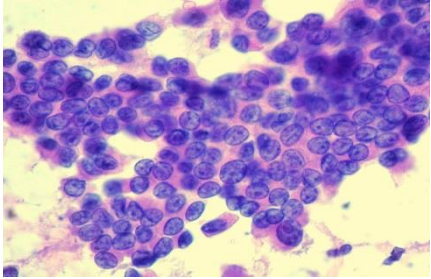


Patient Name: **Smith, Jane**
 Sex: Female
 Date of Birth: 12/08/1929
 Age: 85
 Date Collected: 01/01/2015
 Date Received: 01/01/2015
 Date Reported: 01/02/2015

Accession Number: **C15 - 123456**
 UP ID: 012354
 Ordering Client: The Best Doctor
 Ordering Physician: The Best Doctor
 Client Address: 1 Westchester Plaza
 Elmsford, New York 10523
 Telephone: 914-307-1678 Fax: 914-345-3064
 CC Physician:

CYTOLOGY REPORT

<p>Smith, Jane</p> <p>C15 – 123456</p> <p>01/02/2015</p>	<p>INTERPRETATION</p> <p style="color: red; text-align: center;">MALIGNANT (Bethesda category VI) Papillary thyroid carcinoma</p>	
---	--	---

Microscopic Description:

The specimen reflects a cellular sample composed of neoplastic cells with significant nuclear pleomorphism including overlapping nuclei and small 3-dimensional clusters. Both nuclear grooves and nuclear inclusions are easily identified. Rare psammoma bodies are present. Colloid is virtually absent. The cell block demonstrates both follicular and papillary patterns of growth.

The cytological features are consistent with **papillary thyroid carcinoma**.

Source of Specimen:

FNA – Left Thyroid.

Gross Description:

8ml clear pink fluid in Cytolyt, Specimen is processed for Cell block and Cytospin.

Clinical History :

Left Thyroid Solid Nodule, 3.7 cm

Screened By: UP Cytotech, CT (ASCP)

Electronically Signed By: UP Pathologist, M.D.
 Date: 01/02/2015

**END OF
REPORT**