

Patient Name : **DOE-TEST, JANE-TEST**

Patient Rec. #:

Date of Birth: 01/01/1980 Age: 36

Sex: Female

Date Collected: 09/13/16

Date Received: 09/13/16

Date Reported: 09/13/16

Specimen Number: **S16-001348**

UP ID:

Ordering Client: THE BEST DOCTOR

Ordering Physician: THE BEST DOCTOR

Client Address: 1 Westchester Plaza

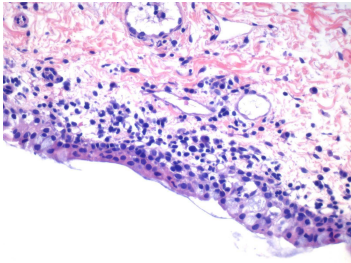
ELMSFORD, NY 10523

Telephone: (914) 307-0167

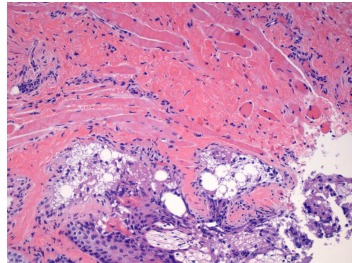
Fax: (914) 345-3064

CC Physician:

PATHOLOGY REPORT



Chronic conjunctivitis



Extracellular lipid material

Specimen - Left lower lid - Chalazion

DIAGNOSIS:

CHRONIC CONJUNCTIVITIS WITH GOBLET CELL HYPERPLASIA

-Stromal fibrosis with chronic inflammation

-Extracellular lipid material is identified

-Hyperplastic alterations of meibomian glands with squamous metaplasia

GROSS DESCRIPTION: Received in formalin, two tan/white tissues, measuring 0.5 x 0.3 x 0.2 cm. Specimen is entirely submitted in one cassette.

NOTES: This biopsy displays predominantly chronic inflammatory changes with scarring of the stroma, accompanied changes in the meibomian gland that are frequently associated with chalazion. The usual florid inflammatory reaction is, however, not present in this biopsy.

CLINICAL HISTORY

Chalazion left eyelid

Electronically Signed by: UP Pathologist M.D.

Date: 09/13/2016