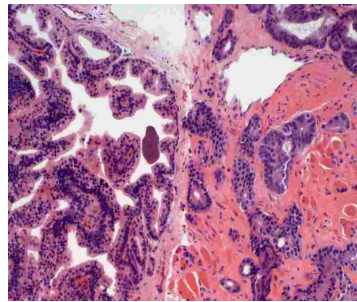
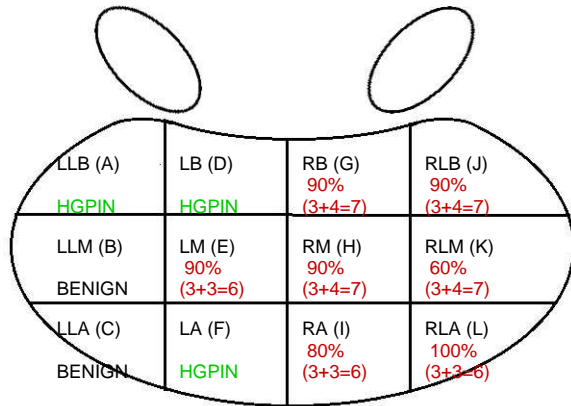


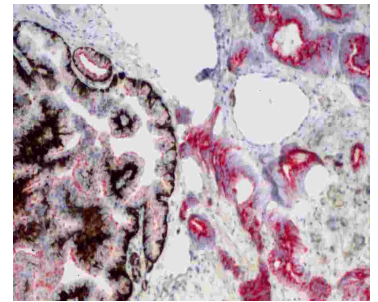
Patient Name: **SMITH, JOHN**  
 Patient Rec. #:   
 Date of Birth: 01/01/1954      Age: 59  
 Sex: Male  
 Date Collected: 10/15/13  
 Date Received: 10/15/13  
 Date Reported: 06/21/16

Specimen Number: **S13-999999**  
 UP ID:   
 Ordering Client: THE BEST DOCTOR  
 Ordering Physician: THE BEST DOCTOR  
 Client Address: 1 Westchester Plaza  
 ELMSFORD, NY 10523  
 Telephone: (914) 307-0167      Fax: (914) 345-3064  
 CC Physician:

## UROLOGIC PATHOLOGY REPORT



S13-999999 HGPIN and Adeno



S13-999999 HGPIN and Adeno

**DIAGNOSIS:**

**A, D, F: Chronic prostatitis with focal glandular atrophy and small glands, focal HGPIN. IHC stains for CK903(HMWCK), p63 and Racemase(AMACR) confirms HGPIN.**

**B, C: Benign prostatic glands and stroma.**

**E: Prostatic Adenocarcinoma, Gleason's score (3+3=6), 90% of core segment involved. IHC stains for CK903(HMWCK), p63 and Racemase(AMACR) confirms adenocarcinoma.**

**G, H: Prostatic Adenocarcinoma, Gleason's score (3+4=7), 90% of core segment involved. IHC stains for CK903(HMWCK), p63 and Racemase(AMACR) confirms adenocarcinoma.**

**I: Prostatic Adenocarcinoma, Gleason's score (3+3=6), 80% of core segment involved.**

**J: Prostatic Adenocarcinoma, Gleason's score (3+4=7), 90% of core segment involved.**

**K: Prostatic Adenocarcinoma, Gleason's score (3+4=7), 60% of core segment involved.**

**L: Prostatic Adenocarcinoma, Gleason's score (3+3=6), 100% of core segment involved.**

GLEASON SCORE & PERCENT CARCINOMA											
A	B	C	D	E	F	G	H	I	J	K	L
				(3+3=6)		(3+4=7)	(3+4=7)	(3+3=6)	(3+4=7)	(3+4=7)	(3+3=6)
				90%		90%	90%	80%	90%	60%	100%

**MICROSCOPIC DESCRIPTION**

**GROSS DESCRIPTION**

- A. In Formalin, One segment, 18mm in length, 0.5mm in thickness, 1 cassette.
- B. In Formalin, One segment, 20mm in length, 0.5mm in thickness, 1 cassette.
- C. In Formalin, One segment, 17mm in length, 0.5mm in thickness, 1 cassette.

(Continued on Next Page)

Patient Name: **SMITH, JOHN**

Specimen Number: **S13-999999**

- D. In Formalin, One segment, 18mm in length, 0.5mm in thickness, 1 cassette.
- E. In Formalin, One segment, 16mm in length, 0.5mm in thickness, 1 cassette.
- F. In Formalin, One segment, 20mm in length, 0.5mm in thickness, 1 cassette.
- G. In Formalin, One segment, 15mm in length, 0.5mm in thickness, 1 cassette.
- H. In Formalin, One segment, 17mm in length, 0.5mm in thickness, 1 cassette.
- I. In Formalin, One segment, 11mm in length, 0.5mm in thickness, 1 cassette.
- J. In Formalin, One segment, 13mm in length, 0.5mm in thickness, 1 cassette.
- K. In Formalin, One segment, 17mm in length, 0.5mm in thickness, 1 cassette.
- L. In Formalin, One segment, 18mm in length, 0.5mm in thickness, 1 cassette.

**CLINICAL HISTORY**

Elevated PSA: 91.2 ug% (2012); 94.3 ug% (04/2013); 106.7 ug% (01/06/2013)

Electronically Signed by: UP Pathologist M.D.

Date: 01/15/2014