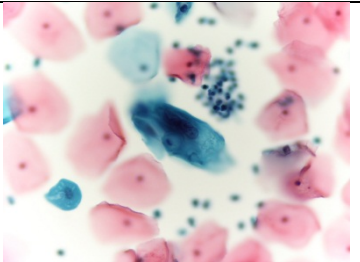


Patient Name: Jane Smith
 Sex: Female
 Date of Birth: 04/27/1990
 Age: 23
 Date Collected: 03/18/2013
 Date Received: 03/18/2013
 Date Reported: 03/19/2013
 Specimen: Urine

Accession Number: C13 - 123456
 UP E ID: 09876
 Ordering Physician: The Best Doctor
 Client Account No. NY36912
 Client Address: 1 Westchester Plaza
 Elmsford, New York 10523
 Telephone: 914-307-01678
 Fax: 914-345-3064

CYTOLOGY REPORT

<p>Smith, Jane</p> <p>C13 – 123456</p> <p>3/19/2013</p>	<p>INTERPRETATION</p> <p>EPIRHEALIAL CELL ABNORMALITY PRESENT</p> <p>Low-Grade Squamous Intraepithelial Lesion</p>	
---	---	---

Source of Specimen: Voided Urine

Gross Description: Specimen received in CytoLyt fixative, labeled with patient's name and Urine, is 85 ml of cloudy yellow fluid. One ThinPrep slide is prepared. Residual cell pellet is prepared for a cell block. Half of the specimen is submitted for UroVysion testing.

Clinical History: Malignant neoplasm of bladder

Cell Block: Many Squamous cells

Notes: The cytologic pattern is suggestive of a catheterized specimen.

Screened By: UP Cytotech, CT (ASCP)

Electronically Signed By: UP Pathologist, M.D.
 Date: 03/19/2013

END OF REPORT