

Patient Name: **DOE, JANE**

 Specimen Number: **C24-000084**

Patient Rec. #:

Alliance ID:

Date of Birth: 05/19/1958

Age: 65

Ordering Client: THE BEST PHYSICIAN

Sex: Female

Ordering Physician: THE BEST PHYSICIAN

Date Collected: 01/25/24

Client Address: 7200 W Camino Real, Suite 330

Date Received: 01/26/24

Boca Raton, FL 33433

Date Reported: 01/26/24

Telephone: (561) 453-1234

Fax: (561) 453-1238

CC Physician:

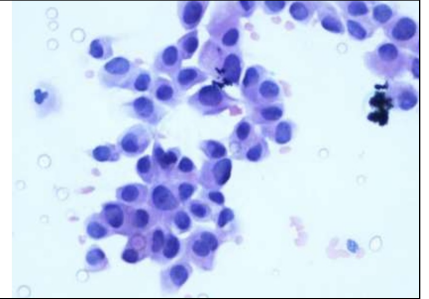
**CYTOLOGY BREAST FNA REPORT**
**DOE, JANE**
**INTERPRETATION**

Specimen #: C24-000084

**POSITIVE FOR MALIGNANT CELLS  
 DUCTAL CARCINOMA**

Date: 01/25/24

The aspiration demonstrates groups of malignant cells consistent with ductal carcinoma


**MICROSCOPIC DESCRIPTION** The malignant cells: Enlarged, hyperchromatic nuclei and conspicuous nucleoli with high N/C ratio. The intracytoplasmic lumen is also noted.

**SOURCE OF SPECIMEN** Fine needle aspiration, right breast, 3 o'clock

**SPECIMEN ADEQUACY** Satisfactory for evaluation

**GROSS DESCRIPTION** FNA, 30 ml of pale pinkish clear fluid is received in CytoLyt fixative. 2 CellSolutions F50 slides prepared. Residual cell pellet is prepared for cell block. (CellSolutions F50: PAPx1 & H&Ex1 ; Cell block: 2levels, H&Ex2)

**CLINICAL HISTORY** Malignant neoplasm of upper-outer quadrant of right female breast (C50.411)

**ADDITIONAL TESTS** The immunohistochemistry studies to follow - ER/PR/Ki-67/HER2

SCREENED BY: Woosung J Park, CT(ASCP)

REVIEWED BY: Electronically REVIEWED BY: Ali Tamsen, M.D. Board Certified in Anatomic Pathology

Date: 01/26/2024 Time: 14:50:45

**CPT CODES** 88173

**END OF REPORT**