

Patient Name: **DOE, JANE**

 Specimen Number: **C24-000534**

Patient Rec. #:

Alliance ID:

Date of Birth: 05/19/1958

Age: 66

Ordering Client: THE BEST PHYSICIAN

Sex: Female

Ordering Physician: THE BEST PHYSICIAN

Date Collected: 05/22/24

Client Address: 7200 W Camino Real

Date Received: 05/23/24

BOCA RATON, FL 33433

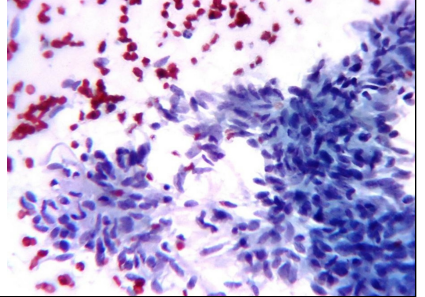
Date Reported: 05/29/24

Telephone: (561) 453-1234

Fax: (561) 453-1238

CC Physician:

CYTOLOGY REPORT

DOE, JANE Specimen #: C24-000534 Date: 05/22/24	INTERPRETATION POSITIVE FOR MALIGNANT CELLS SARCOMA/SPINDLE CELL NEOPLASM, HIGH GRADE	
--	--	---

MICROSCOPIC DESCRIPTION Cytology composed of spindle shaped tumor cells with elongated vesicular to hyperchromatic nuclei with occasional prominent nucleoli.

SOURCE OF SPECIMEN Right knee, subcutaneous/soft tissue, fine needle aspiration

SPECIMEN ADEQUACY Satisfactory for evaluation

GROSS DESCRIPTION FNA, 8 ml of pale pinkish clear fluid is received in CytoLyt fixative. 2 CellSolutions F50 slides prepared. Residual cell pellet is prepared for cell block. (CellSolutions F50: PAPx1 & H&Ex1 ; Cell block: 2levels, H&Ex2)

CLINICAL HISTORY Subcutaneous mass near the right knee, 3 cm

CELL BLOCK The cell block sections exhibit spindle cells with hyperchromatic nuclei consistent with spindle cell malignant tumor.

SCREENED BY: Woosung J Park, CT(ASCP)

REVIEWED BY: Electronically REVIEWED BY: Ali Tamsen, M.D. Board Certified in Anatomic Pathology
 Date: 05/29/2024 Time: 12:06:20

CPT CODES 88173

_____ **END OF REPORT** _____